

LETTER TO THE EDITOR

Open Access



Intra-operative pinkish-red discoloration of urine: rule out anesthetic drug as a cause

Rajnish Kumar^{*}, Nishant Sahay and Shagufta Naaz

Sir,

Pink-red discoloration of urine during anesthesia has been reported with the use of propofol, but it must be ruled out. Other drugs such as losartan, amlodipine, atorvastatin, and fenofibrate act as secondary uricosurics and can cause pink urine. Red color urine has been also found in an inherited condition that affects red cell and hemoglobin-like sickle cell anemia, thalassemia, and porphyria. We present a case of a 60-year-old female, ASA physical status 1, who was posted for sacrocolpopexy for vaginal prolapse. Her all laboratory parameters were within normal limits. She fasted after midnight. General anesthesia was induced using injection midazolam 1 mg, fentanyl 120 µg, propofol 100 mg, and atracurium 30 mg for tracheal intubation. Anesthesia was maintained with oxygen, air, and sevoflurane. Foley's catheterization was done under an aseptic technique without trauma. Pinkish-red color urine was seen in a urine bag (Fig. 1). Open sacrocolpopexy was started. The urine color was gradually changed to clear in 2 h. She received only intravenous ceftriaxone 1 g 1 h before induction. Surgery underwent uneventfully and she was shifted to the recovery room, and her discharge from the hospital was uneventful. We enquired about the history of the patient and were told that she had taken approximately 150 ml of beetroot juice three times the day before surgery without informing the doctors on duty, when she was put on a liquid diet for

preparation for surgery. In routine microscopy of urine, no red blood cells were detected, and the urine culture report was sterile.

Deep pink to deep red discoloration of urine after the consumption of beetroot is called beeturia. It is a benign condition and prevalent in 10–14% of the population. Pinkish-red discoloration of urine is due to a compound in beets called betanin, which gives the beetroot vegetable its red pigment. People with low stomach acid will not break down the pigment called betanin in beets, and it gets absorbed in the intestine, enters the bloodstream, and gets excreted by the kidneys. Patients who have iron deficiency and eat beetroot with foods that contain a substance called oxalate make urine color change to pink-red. In anesthesia drugs, case reports have been published that propofol infusion mainly causes green discoloration of urine in intensive care unit patients, but pink discoloration of urine has also been reported on its infusion and single use (Barbara et al. 2012; Tucker and Perazella 2019). Pink discoloration of urine developed in the clinical condition of relative dehydration with oliguria and propofol metabolites were condensed and crystallized into the urine (Masuda et al. 1996). The authors have also postulated that the use of propofol causes an increase in the excretion of urates, which can condition pink urine (Del Carpio-Orantes et al. 2017). We conclude that pinkish-red discoloration of urine after beetroot ingestion is also an uncommon finding, but during anesthesia, we must exclude any anesthetic drug involvement.

*Correspondence:

Rajnish Kumar
drraj76pmch@gmail.com
Department of Anaesthesiology, All India Institute of Medical Science,
Room no 503, B5A, IPD Building, Patna, India

Abbreviation

ASA American Society of Anesthesiologists



© The Author(s) 2023. **Open Access** This article is licensed under a Creative Commons Attribution 4.0 International License, which permits use, sharing, adaptation, distribution and reproduction in any medium or format, as long as you give appropriate credit to the original author(s) and the source, provide a link to the Creative Commons licence, and indicate if changes were made. The images or other third party material in this article are included in the article's Creative Commons licence, unless indicated otherwise in a credit line to the material. If material is not included in the article's Creative Commons licence and your intended use is not permitted by statutory regulation or exceeds the permitted use, you will need to obtain permission directly from the copyright holder. To view a copy of this licence, visit <http://creativecommons.org/licenses/by/4.0/>.

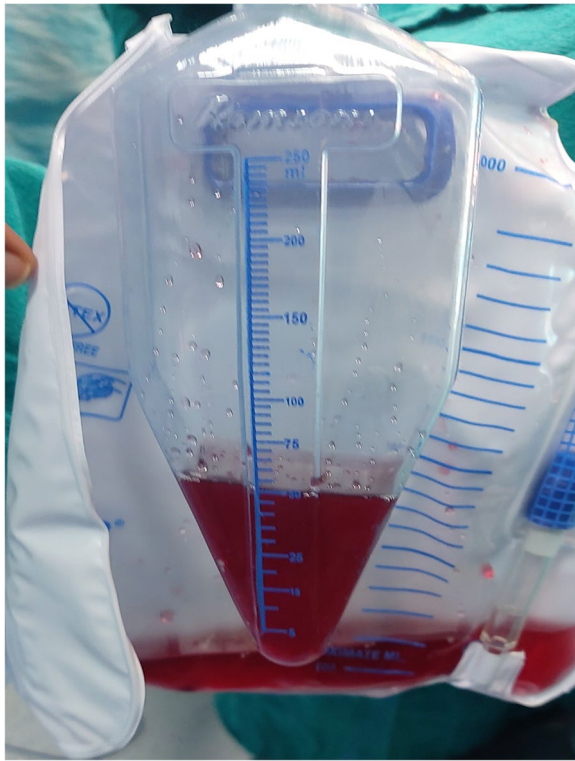


Fig. 1 Urometer showing pinkish-red color urine

Acknowledgements

Not applicable.

Authors' contributions

RK: manuscript preparation and concepts. NS: Manuscript review. SN: Manuscript editing. The authors have read and approved the final manuscript.

Funding

Nil

Availability of data and materials

Not applicable.

Declarations

Ethics approval and consent to participate

Ethical approval is not required for the publication of these case reports. The patient was informed about the procedure, and a written informed consent was obtained.

Consent for publication

Written permission/consent of the patient for the purpose of publication in an educational medical journal was obtained from the patient.

Competing interests

The authors declare that they have no competing interests.

Received: 26 January 2022 Accepted: 12 February 2023

Published online: 27 February 2023

References

- Barbara DW, Whalen FX, Hemmings HC (2012) Propofol induction resulting in green urine discoloration. *Anesthesiology* 116:924
- Del Carpio-Orantes L, Elizalde- Bernal RJJ, Villegas-Dominguez JE, Morales-Ocon JE, Tejero-Da Silveira RK (2017) Pink urine syndrome. *AMJ* 10(3):199–201
- Masuda A, Koki H, Toshihiko S, Yusuke I (1996) Pink urine during propofol anesthesia. *Anesth Anal* 83:666–667
- Tucker BM, Perazella MA (2019) Pink urine syndrome: a combination of insulin resistance and propofol. *Kidney Int Rep* 4(1):30–39

Publisher's Note

Springer Nature remains neutral with regard to jurisdictional claims in published maps and institutional affiliations.

Submit your manuscript to a SpringerOpen[®] journal and benefit from:

- ▶ Convenient online submission
- ▶ Rigorous peer review
- ▶ Open access: articles freely available online
- ▶ High visibility within the field
- ▶ Retaining the copyright to your article

Submit your next manuscript at ▶ [springeropen.com](https://www.springeropen.com)